Sarcoidosis - Renal Manifestation

AMRITA VISHWA VIDYAPEETHAM UNIVERSITY
Established u/s-3 of the UGC Act 1956
Amrita Institute of Medical Sciences
Healthcare, Education & Research

Dr.Athulya sadeesh, Dr.Seethalekshmy, Dr. Annie Jojo
Dept of Patholology, Amrita Institute of Medical Sciences, Kochi, Kerala

Abstract

- Sarcoidosis is an illness of granulomatous inflammation with multi-organ association
- Commonly involving the lung and reticuloendo thelial system.
- Involvement of the kidney in sarcoidosis is rare and may manifest as proteinuria, hematuria, hypercalciuria, or nephrocalcinosis.
- Sarcoidosis presenting initially with renal manifestation is even more rare
- Here we report 3 cases of sarcoidosis presented with renal manifestation and diagnosed by renal biopsy.

CASE-1

- 42 Yr old Male,
- Diabetic :2yrs on oral hypoglycemic, Detected mild renal dysfunction when evaluated for nephrolithiasis.
- Polyarthralgia : 2 months. No HTN, paresthesia or dimness of vision. No high coloured urine. No family history of renal disease.
- Systemic examination :WNL, No neuropathy or retinopathy.
- Evaluation showed sub nephrotic proteinuria (1.5 gms/24 hrs), persistent microhematuria, mild renal dysfunction (s.creat ;2.6 mg%).
- Chest x ray was normal.
- S.Ca: 13.4 mg/dl ,S.P: 4.5 mg/dl, S PTH : 8.3 pg/ml(normal:15-65), S.alb 3.8gm/dl, Serum alkaline phosphatase: 115 IU/l, ANA profile was negative.
- Immunoflourescence study: negative.
- He was found to have xerophthalmia and xerostomia. Schirmers test : positive.
- Lip biopsy showed minor salivary glands : non caseating granulomas. Many giant cells showing typical asteroid bodies.

- Renal biopsy done
- **Diagnosis : Renal Biopsy:** Sarcoidosis (Schirmers test positivity, hypercalcemia, granulomatous inflammation of both kidney and salivary glands and a negative ANA profile).

CASE-2

- 48 yr old female
- Systemic hypertension - 2 yr. B/L iridocyclitis x 8 months. Polyarthralgia - 2 months. Hepatomegaly. Froathy urine.
- BP: 130/90. 24 hr UP: 1.4gm%. S.creat: 3.8mg%. S.Alb: 4.6mg%. Urine alb: trace. ESR: 25mm/1hr. ANA, RA factor and ANCA negative
- Clinical impression: ? IgA N.

- Renal biopsy done
- Tubular atrophy and loss amount of 30% of cortex. Tubules show hyaline casts.
- Interstitium show diffuse moderate chronic inflammatory infiltrate composed of lymphocytes, plasma cells and multiple, discrete, non caseating granulomas composed of collections of epithelioid cells, both Langhan's and foreign body type of giant cells. (AFB and PAS stain - negative) Many giant cells show laminated concretions.

- Interstitial fibrosis amount to 10 - 20% of the cortex.
- A large calibre artery and interlobular arteries show moderate intimal fibroplasia and reduplication of internal elastic lamina. Arteries and arterioles show hyaline arterio and arteriolosclerosis.

- **Immunofluorescence studies:**
  Tissue for IF show 3 glomeruli, which are negative for IgG, IgA, IgM, C3 and C1q.
- **Diagnosis:**
  Renal Biopsy: Granulomatous interstitial nephritis, (morphology favour sarcoidosis) with moderate hypertensive vascular changes

CASE-3

- 47yr old male
- k/c/o Type 2 Diabetes mellitus and systemic hypertension.
- c/o anorexia, myalgia and acute weight loss (around 12kg within 1 month). H/o intermittenet fever.
- Hypercalcemia (S.Ca. 12.6) and acute renal failure (S.Creat:3.5), S.Alb:3.2, S.Globulin:4.5, Blood urea:69, Total protein:7.7gm. S.Ca. 12.4, S.Uric acid 8.0. 24 hr UP: 681.5mg. Crystals: Ca. oxalate. 24 hr U Ca. 432mg. Bence jones protein: Negative.
- Clinical Impression: ? Drug induced interstitial nephritis.? Multiple myeloma

- Renal biopsy done
- Glomeruli appear near normal in size.
- Tubules show mild epithelial vacuolation and calcific crystals in the lumina. A few tubules also reveal lymphocytic infiltration of epithelium.
- Interstitium also reveal 2 discrete non caseating microgranulomas composed of epithelioid cells and giant cells. 2 similar granulomas are noted in the renal capsule also)
- Interstitium also reveal a few calcific lamellated concretions(von kossa positive).
- Immunoflourescence study: negative
- **Diagnosis: Renal Biopsy:** Acute on chronic tubulointestitial nephritis with interstitial microgranulomas, mild global glomerulo sclerosis and hypertensive vascular changes. Correlating with clinical and biochemical findings, suggestive of Sarcoidosis

Microgranulomas composed of epithelioid cells and giant cells

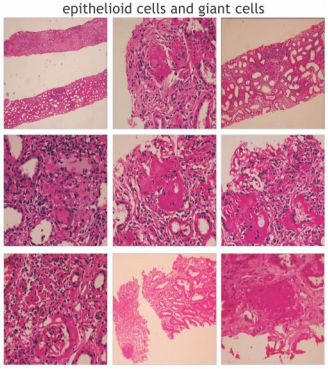

Masson trichrome

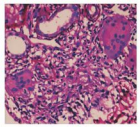

PAS (Negative)

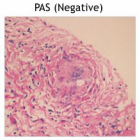

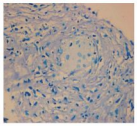

AFB (Negative)

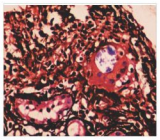

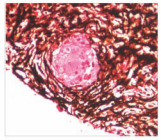

Jones Silver

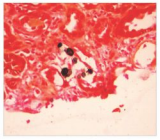

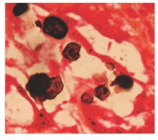

Von kossa stain (calcific lamellated concretions)

Discussion

- Sarcoidosis is an inflammatory disorder characterized by noncaseating epithelioid cell granulomas commonly involving the lung and reticuloendothelial system.
- Pulmonary manifestations-common.
- 10%-30% of sarcoidosis presents with extra pulmonary manifestation.
- ACE levels are seeing increased in patient serum
- Renal manifestations
  - Hypercalcuria (40 - 50%)
  - Hypercalcemia (5 -10%)
  - Nephrocalcinosis
  - Granulomatous interstitial nephritis
  - Rarely glomerulonephritis
- **Reported patterns of kidney injury:**
  - Interstitial nephritis (with or without granulomatous inflammation),
  - Minimal change disease,
  - Focal segmental glomerulosclerosis,
  - Membranous glomerulopathy,
  - IgA nephropathy,
  - Membranoproliferative glomerulo nephritis crescentic glomerulonephritis (with positive or negative [ANCA] test results).

Pathogenesis

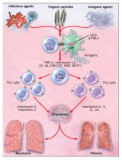

Hypercalcemia in sarcoidosis

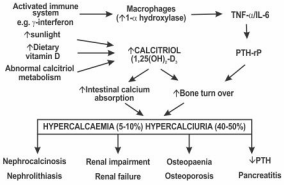

- Main stay of treatment of sarcoid with renal involment is glucocorticoids.
- Renal transplantation is safe in patients with sarcoidosis but we must keep in mind the disease can recurr in the allograft.
- In conclusion,sarcoidosis is a complex disease and presents both a diagnostic and management challenge

References

- The new england journal of medicineN Engl J Med 2007;357:2153-65. Michael C. Iannuzzi, M.D., Benjamin A. Rybicki, Ph.D., and Alvin S. Teirstein, M.D.
- Boeck C. Multiple benign sarcoid of the skin. J Cutan Genitourin Dis 1899;17:5450.
- Baughman RP, Lower EE, du Bois RMSarcoidosis. Lancet 2003; 361:1111
- Rybicki BA, Major M, Popovich J, Jr., Maliarik MJ, Iannuzzi MC.: Racial differences in sarcoidosis incidence: A 5-year study in a health maintenance organization. Am J Epidemiol 145: 234-241, 1997
- Pietinalho A, Hiraga Y, Hosoda Y, Lofroos AB, Yamaguchi M, Selroos O.: The frequency of sarcoidosis in Finland and Hokkaido, Japan. A comparative epidemiological study. Sarcoidosis 12: 61-67, 1995

Acknowlegement

Dr. Sandeep Varma, Sree Gokulam Medical College, TVM
Dr. Mamen M John, Medical Trust Hospital, Cochin
Dr. K P Jayakumar, Kottayam Govt. Medical College